

## —Report on Experiments and Clinical Cases—

## A Case of Infantile Cortical Hyperostosis

Hüseyin Çaksen<sup>1</sup>, Yaşar Cesur<sup>1</sup>, Dursun Odabaş<sup>1</sup>, Halil Aslan<sup>2</sup> and Levent Rastgeldi<sup>1</sup>Departments of <sup>1</sup>Pediatrics and <sup>2</sup>Radiology, Yüziüncü Yıl University of Medicine, Van, Türkiye**Abstract**

Infantile cortical hyperostosis (ICH) is usually a self-limited disease of infancy with bony changes, soft tissue swelling, fever, irritability, decreased appetite, and decreased movement of the affected bones. Its description in isolated patients or in multiple members of families suggests the existence of two different forms, namely a sporadic form and a familial form with incomplete penetrance. In this article, we report a 2.5-month-old girl with ICH of sporadic form, due to unusual presentation. (J Nippon Med Sch 2001; 68: 442—443)

**Key words:** infantile cortical hyperostosis

**Introduction**

Infantile cortical hyperostosis (ICH), described by Caffey and Silverman<sup>1</sup> in 1945, is usually a self-limited disease of infancy with bony changes, soft tissue swelling, fever, irritability, decreased appetite, and decreased movement of the affected bones. This condition presumably has an autosomal dominant mode of inheritance. Its description in isolated patients or in multiple members of families suggests the existence of two different forms, namely a sporadic form and a familial form with incomplete penetrance<sup>2-4</sup>. Here, we report a sporadic case of ICH due to unusual presentation.

**Case Report**

A 2.5-month-old girl was admitted with a 2-week history of pain and swelling of the forearms and thighs. No maternal use of medication or antepartum illnesses were reported, and the family history was non-contributory. On physical examination she had bilateral widespread pain and swelling over the forearm

and thigh, but no redness or localizing fever. The remaining physical examination findings were normal. Laboratory studies disclosed: normal urine analysis, hemoglobin 11g/dl, leukocyte count 8,400/mm<sup>3</sup>, and a sedimentation rate of 11mm/h. Biochemical analysis showed: calcium 10.6mg/dl, inorganic phosphorus 5.9 mg/dl, alkaline phosphatase 735U/L, serum parathyroid hormone level 10pg/ml, creatine kinase 62mg/dl, serum total thyroxine concentration 15.7µg/dl, serum free thyroxine concentration 1.8ng/dl, and thyroid stimulating hormone level 3.08mIU/ml. The VDRL test for syphilis was negative. Roentgenograms of the mandible, radii, ulnae and femur showed massive cortical hyperostosis (**Fig. 1—3**). The patient was not given any drug, and her symptoms and signs gradually decreased during the follow-up. At the 6<sup>th</sup> month of follow-up the symptoms disappeared, but the bone changes continued mildly.

**Discussion**

The clinical picture can vary, but certain characteristics are commonly seen. Classically, ICH is a disease of young infants and is characterized by soft tissue

Correspondence to Hüseyin Çaksen, MD, Assistant Professor, Department of Pediatrics, Yüziüncü Yıl University of Medicine, Van, Türkiye

E mail: huseyincaksen@hotmail.com

Journal Website (<http://www.nms.ac.jp/jnms/>)

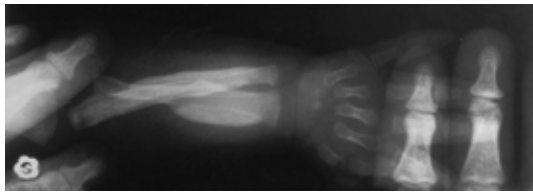


Fig. 1 Roentgenogram of the right radii and ulna showing massive cortical hyperosteosis.

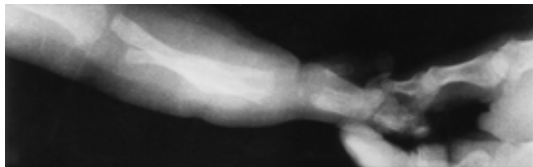


Fig. 2 Roentgenogram of the right radii and ulna showing massive cortical hyperosteosis.

swelling over the affected bones, fever, irritability, and periods of remission and exacerbation. The age of onset of disease is said to be 9 to 11 weeks age<sup>2,5,6</sup>. It rarely, if ever, appears after 5 months of age, it is sometimes present at birth and has been identified by X-rays in the fetus in utero<sup>3,7</sup>. Rarely, late recurrence or persistence of symptoms with deformity have been reported<sup>3</sup>. In accordance with the literature, our case's age was 2.5-month-old, and she had bilateral widespread pain and swelling over the forearm and thigh and the symptoms completely disappeared during the follow-up.

The radiographic findings are those of subperiosteal new bone formation of the bones beneath the areas of soft tissue swelling and often elsewhere. These changes have been reported in all portions of the skeletal system, except in the vertebrae. By the age of 3 years the findings of radiographic examinations are within normal limits<sup>5,6</sup>. On the other hand it has been noted that in the sporadic type the mandible, ulna, clavicle and ribs are the bones most frequently affected, while in the familial form, the tibia is predominantly involved<sup>2,3,8</sup>. In our patient cortical hyperosteosis was established in the mandible, radii, ulnae and femur, but not in the tibia. These features support the placement of our patient in the group of sporadic type of ICH.

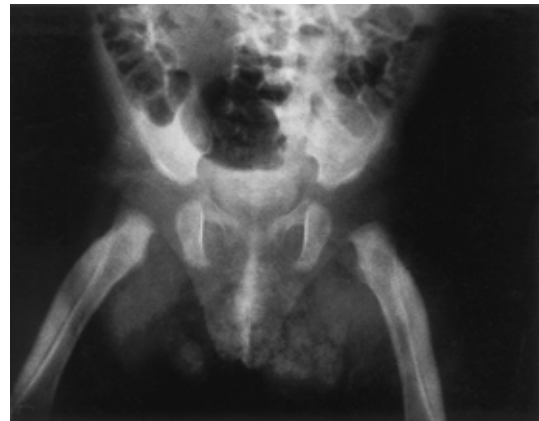


Fig. 3 Severe cortical hyperosteosis appeared in both femurs.

The prognosis of ICH is excellent<sup>2</sup>. Symptomatic therapy consisting of the use of analgesics, such as aspirin, and sedatives, such as phenobarbital, is usually adequate<sup>5,6</sup>. Our patient was not given any drugs, but her symptoms resolved without treatment.

#### References

1. Caffey J, Silverman W: Infantile cortical hyperostosis, preliminary report on new syndrome. *Am J Radiol* 1945; 54: 1-16.
2. Saul RA, Lee WH, Stevenson RE: Caffey's disease revisited. Further evidence for autosomal dominant inheritance with incomplete penetrance. *Am J Dis Child* 1982; 136: 56-60.
3. Borochowitz Z, Gozal D, Missellevitch I, Aunallah J, Boss JH: Familial Caffey's disease and late recurrence in a child. *Clin Genet* 1991; 40: 329-335.
4. Emmery L, Timmermans J, Christens J, Fryns JP: Familial infantile cortical hyperostosis. *Eur J Pediatr* 1983; 141: 56-58.
5. Tampas JP, Van Buskirk FM, Peterson OS Jr., Soule AB: Infantile cortical hyperostosis. *JAMA* 1961; 175: 167-169.
6. Newberg AH, Tampas JP: Familial infantile cortical hyperostosis: An update. *Am J Radiol* 1981; 137: 93-96.
7. Lecolier B, Bercau G, Gonzales M, Afriat R, Rambaud D, Mulliez N, de Kermadec S: Radiographic, haematological, and biochemical findings in a fetus with Caffey disease. *Prenatal Diag* 1992; 12: 637-641.
8. MacLachlan AK, Gerrard JW, Houston CS, Ives EJ: Familial infantile cortical hyperostosis in a large Canadian family. *Can Med Assoc J* 1984; 130: 1172-1174.

(Received, March 22, 2001)

(Accepted, May 17, 2001)