



# Current management of hypertrophic pyloric stenosis

Gudrun Aspelund, MD, Jacob C. Langer, MD

*From the Division of General Surgery, University of Toronto, Hospital for Sick Children, Toronto, Ontario, Canada.*

## INDEX WORDS

Pyloric stenosis;  
 Infant;  
 Child;  
 Pyloromyotomy;  
 Surgical procedures;  
 Complications

Hypertrophic pyloric stenosis (HPS) is a common condition affecting infants that presents with progressive projectile nonbilious vomiting. The pyloric portion of the stomach becomes abnormally thickened and manifests as gastric outlet obstruction. The cause is unknown. Pyloromyotomy remains the standard of treatment and outcome is excellent. This article reviews the diagnostic work up and imaging, preoperative resuscitation, the various surgical approaches used, and the effect of subspecialty training on outcomes after pyloromyotomy. Postoperative care and the variety of postoperative feeding regimens applied after pyloromyotomy are reviewed, as well as intra- and postoperative complications. Finally, medical management, in lieu of surgery, is discussed.

© 2007 Elsevier Inc. All rights reserved.

Hypertrophic pyloric stenosis (HPS) is a condition affecting infants, in which the pyloric portion of the stomach becomes abnormally thickened and manifests as obstruction to gastric emptying. The infant presents in the first 2 to 12 weeks of life with forceful or projectile nonbilious vomiting after feeding. With protracted vomiting, the emesis may become blood-tinged because of gastritis. Jaundice occurs in about 2% of infants with HPS secondary to defective hepatic glucuronyl transferase activity, which resolves after surgery.<sup>1</sup> The incidence of HPS is about 2 to 4 per 1000 live births in Western populations,<sup>2</sup> but it is less common in African and Asian populations, with a male-to-female ratio of approximately 4:13. The basis for higher male susceptibility is unknown. There is evidence both for and against an increased incidence in the first-born child, and there is familial clustering of HPS, but not in a Mendelian pattern.<sup>3</sup> HPS appears to be more common in bottle-fed infants,<sup>4</sup> in rural populations,<sup>2</sup> and in the summer months (Langer and coworkers, unpublished data).

The first clinical description of HPS was by Fabricius Hildanus in 1627, but Harald Hirschsprung's seminal article in 1888 led to our modern understanding of the condition.<sup>5</sup> Although HPS is the most common surgical condition producing emesis in infancy,<sup>1</sup> its etiology is unknown. Whether the condition is congenital or acquired is debated.<sup>6</sup> Neonatal HPS does exist but is very rare.<sup>3</sup> Variations in HPS incidence, trending over time, suggest that unknown environmental factors have an impact.<sup>2</sup> The mechanism underlying the narrow window of diagnosis between approximately 2 and 12 weeks is obscure, but may reflect normal postnatal physiology, such as introduction of enteral feeding, acting on abnormal pyloric tissue.<sup>3</sup> Deficiency of nerve terminals, markers for nerve-supporting cells, peptide containing nerve fibers, mRNA production for nitric oxide synthase and interstitial cells of Cajal have all been found in the muscular layer of the pylorus,<sup>7-11</sup> as well as increased insulin-like and platelet-derived growth factors.<sup>12,13</sup> This abnormal innervation is postulated to lead to failure of relaxation of the pylorus muscle, increased synthesis of growth factors, and subsequent hypertrophy.<sup>14</sup> It is likely that a spectrum of genetic mutations involving the production of nitric oxide may be responsible for many cases of HPS.<sup>15</sup>

---

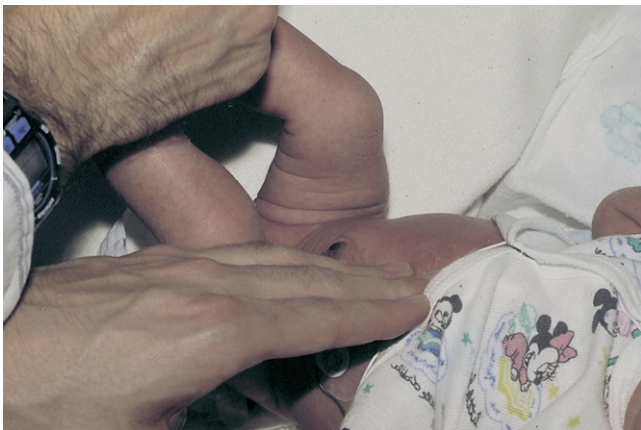**Address reprint requests and correspondence:** Jacob C. Langer, MD, University of Toronto, Division of General Surgery, Hospital for Sick Children, Toronto, 555 University Avenue, Room 1526, Toronto, Ontario M5G 1X8, Canada.

E-mail: jacob.langer@sickkids.ca.

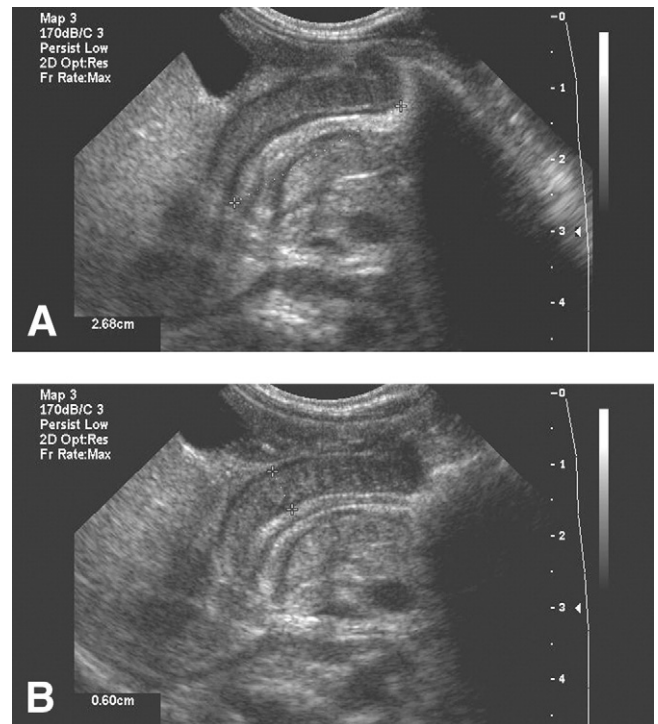
## Preoperative evaluation

The diagnosis is initially suggested by the history. Palpation of a hypertrophied pyloric muscle, or “olive,” is diagnostic and successful in the majority of infants with a 99% positive predictive value<sup>16,17</sup> (Figure 1). Despite the fact that HPS can be diagnosed solely by palpation, there is a trend toward increased reliance on imaging as a substitute or complement to physical examination. In one report, there was a threefold increase in use of imaging between the periods 1974 to 1977 and 1988 to 1991, with a decrease in cases diagnosed by palpation (from 87% to 49%) during the two periods, respectively.<sup>18</sup> Although imaging is highly sensitive, it does not lead to increased accuracy of diagnosis, and it does increase cost.<sup>16</sup> Some have speculated that decline in palpable HPS and therefore increased use of imaging is related to earlier presentation of patients in recent times so that infants are less emaciated, healthier, and more vigorous, and thus more difficult to examine.<sup>19</sup>

Other methods of diagnosis must be used when physical examination is unsuccessful. Fluoroscopic upper gastrointestinal contrast study was first proposed in 1918, and is performed with the child drinking from a bottle.<sup>5</sup> In patients with HPS, there is failure of relaxation of the prepyloric antrum and the pyloric canal is outlined by a *string* of contrast material. The thickened muscle causes an external impression on the gastric antrum, termed the “shoulder sign.” Fluoroscopy can be time consuming and involves radiation. Sensitivity as high as 95% is reported but depends on experience and skill of the examiner.<sup>20</sup> Ultrasonography is noninvasive, can be performed quickly and there is no radiation exposure (Figure 2). Accuracy approaches 100% in experienced hands,<sup>20</sup> with 99.5% sensitivity and 100%



**Figure 1** Palpation of the “olive.” The child’s hips should be flexed to relax the abdominal wall. The abdomen should be palpated gently, focusing on the space midway between the umbilicus and the xiphoid, between the two rectus muscles. If the child is crying, he can be given a bottle of sugar solution or electrolyte solution. If this is unsuccessful, it is useful to palpate with a nasogastric tube in place, while feeding the child. This permits complete abdominal wall relaxation without the stomach filling up and getting in the way. (Color version of figure is available online.)



**Figure 2** Ultrasound documenting increased length (A) and thickness (B) of the pyloric muscle.

specificity.<sup>16</sup> Thickened prepyloric antrum can be demonstrated bridging the distended stomach and duodenal bulb. The hypertrophied pyloric canal may range from 14 mm to more than 20 mm in length and the muscle thickness is variable (from 3 to 5 mm). Real time observation of failure of relaxation of the pyloric canal is important.<sup>21</sup>

## Resuscitation

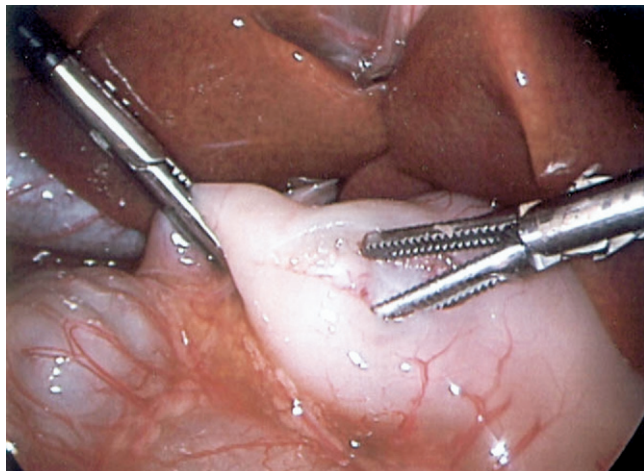
Vomiting of gastric contents leads to depletion of sodium, potassium, and hydrochloric acid, which results in hypokalemic, hypochloremic metabolic alkalosis.<sup>22</sup> The kidneys conserve sodium at the expense of hydrogen ions, leading to paradoxical aciduria. In more severe dehydration, renal potassium losses are also accelerated owing to an attempt to retain fluid and sodium. This cycle can only be broken by adequate fluid and electrolyte replacement. The degree of dehydration can be estimated by clinical examination, urine output, and serum chloride and bicarbonate levels. Surgery should be deferred until the infant is appropriately resuscitated. Most infants with HPS require hospitalization and intravenous fluid replacement therapy, usually consisting of 5% dextrose in 0.45% saline at 1.5 times maintenance rate. Infants with severe dehydration should initially receive boluses with isotonic saline solution. When urine output has been demonstrated, 10 to 20 mEq/L of potassium chloride can be added to the fluids. Resuscitation state is determined by serum electrolytes, skin turgor, moist mucous membranes, and urine output. Serum bicarbonate

less than 28 mEq/dL and serum chloride over 100 mEq/dL are generally required for safe anesthesia.

## Surgical technique

Extramucosal longitudinal splitting of the pyloric muscle without suturing was introduced by Ramstedt in 1912.<sup>23</sup> Traditional surgical access has included midline laparotomy (Fredet in 1908), oblique right upper quadrant incision (Robertson in 1940), and right upper abdominal transverse muscle-splitting incision (Rickham in 1940).<sup>1</sup> In 1986, Tan and Bianchi introduced the circumumbilical incision for pyloromyotomy.<sup>24</sup> Their technique involved a three-quarter circle incision in the natural superior skin fold following the curve of the umbilicus. The peritoneal cavity was then entered through the midline via the linea alba, to the right of the umbilical vein. Many use this skin incision today but enter the abdominal cavity through a transverse fascial incision, ligating the umbilical vein.<sup>25,26</sup> In either case, the pyloric muscle is pulled through the wound, the pyloromyotomy performed, and the pylorus then returned to the abdominal cavity. The scar is retained within the umbilical crease, and thus is hardly visible later. Concerns regarding a higher incidence of complications (wound infections, incisional hernias, mucosal perforations, and serosal tears) compared with the right upper quadrant approach have been raised; these complications have shown a trend toward increased hospital stay, but no long-term sequelae in retrospective reviews.<sup>27</sup> Others found no difference in complications but slightly longer operative time for the umbilical incision, with excellent cosmetic results.<sup>26,28,29</sup>

Alain and coworkers<sup>30</sup> first described a laparoscopic approach to pyloromyotomy in 1991 (Figure 3). This approach has since gained popularity among pediatric surgeons, although potential increased risks with this approach have been a point of concern.<sup>31</sup> A meta-analysis of open versus laparoscopic pyloromyotomy found 8 studies comparing the



**Figure 3** Laparoscopic pyloromyotomy; the 3-mm laparoscopic spreader is shown. (Color version of figure is available online.)

2 methods from 1966 to 2002 and included 595 patients (355 open and 240 laparoscopic).<sup>32</sup> Mucosal perforation and incomplete pyloromyotomy occurred less frequently in the open group, although not significantly so. Three mucosal perforations during the laparoscopic operations were not noticed during the original procedure and were corrected later by an open procedure. Overall, 5% of laparoscopic procedures were converted to open. No difference was found in wound infections or operating time, but time to full feeds and postoperative length of stay were significantly shorter following laparoscopy. Four studies were retrospective reviews and 3 were performed prospectively. Only 1 study was a randomized controlled trial, comparing 10 laparoscopic pyloromyotomies with 10 open umbilical fold pyloromyotomies.<sup>33</sup> Recently a single-center randomized trial was completed, demonstrating no difference between the laparoscopic and open approach for operating time or length of stay.<sup>34</sup> However, the laparoscopic group required less doses of analgesia and experienced fewer episodes of postoperative emesis. A multicenter prospective randomized clinical trial (the “Pi trial”) is currently underway.

A recent retrospective review compared 232 laparoscopic pyloromyotomies with 225 open procedures over a 66-month interval.<sup>31</sup> Overall, the 2 approaches had similar results with no significant difference in rate of complications; however, the distribution and type of complications differed. The conversion rate to open pyloromyotomy was 1.7%. Eight patients in the open group had mucosal perforation compared with 1 in the laparoscopic group. Two laparoscopic patients suffered duodenal injury related to grasping, and 2 patients in the laparoscopic group presented with incisional hernias at the upper abdominal surgical sites. In addition, 5 patients in the laparoscopic group and none in the open group required revision pyloromyotomy. Others have shown decreased complication rates from laparoscopic pyloromyotomy with increased experience.<sup>23</sup>

## Effect of subspecialty training and volume on outcome

Because HPS is so common, and pyloromyotomy is a relatively simple procedure with excellent outcome, the operation is often performed by general surgeons without subspecialty training in pediatric surgery. There has been controversy in the literature about whether outcomes for this operation are the same when the operation is performed by general surgeons as it is when the operation is performed by pediatric surgeons. This controversy has become more heated in recent years, as evidence for volume-outcome and training-outcome relationships accumulates for a variety of surgical procedures.<sup>35-39</sup> A number of retrospective studies have addressed this question, and have suggested that general surgeons’ outcomes are equivalent.<sup>40-43</sup> However, more recent population-based studies have suggested that outcomes such as length of stay and complication rates are

better when the operation is performed by pediatric surgeons compared with general surgeons,<sup>44</sup> or that higher surgeon and hospital volumes lead to improved outcomes.<sup>45,46</sup>

Ly and coworkers analyzed data from the year 2000 in the United States Kid's Inpatient Database, a pediatric-specific database from 27 states, and showed that infants undergoing pyloromyotomy were often treated by low-volume surgeons (<3 pyloromyotomies/year) and at low-volume hospitals (<4 patients with HPS/year).<sup>45</sup> Ten percent of infants were operated on by a surgeon who performed only 1 pyloromyotomy in 2000. From this database, it was not possible to identify whether the surgeons had pediatric surgical training. Higher hospital volume was strongly associated with shorter postoperative stay but no effect of surgeon volume was found on length of stay. Higher surgeon volume was, however, associated with fewer complications, with surgeons with the highest volume (>14 procedures/year) having 90% lower risk than those with the lowest volume (1-5 procedures/year). Similar results were reported by Langer and To,<sup>44</sup> who found that pediatric surgeons had a shorter postoperative stay and a lower rate of mucosal perforation. However, general surgeons with high volumes of pyloromyotomy had complication rates similar to those of pediatric surgeons (Figure 4). Safford and coworkers analyzed 11,003 patients from the 1994 to 2000 US National Inpatient Samples database and evaluated the association between provider volume and outcomes.<sup>46</sup> Patients operated on by low-volume surgeons (<1 case/year) were more likely to have complications compared with those operated on by medium- (1-5 cases/year) or high-volume (>5 cases/year) surgeons. Likewise, patients operated on at low-volume hospitals (<5 cases/yr) were more likely to have complications compared with those operated

at medium- (5-15 cases/year) or high-volume (>15 cases/year) hospitals.

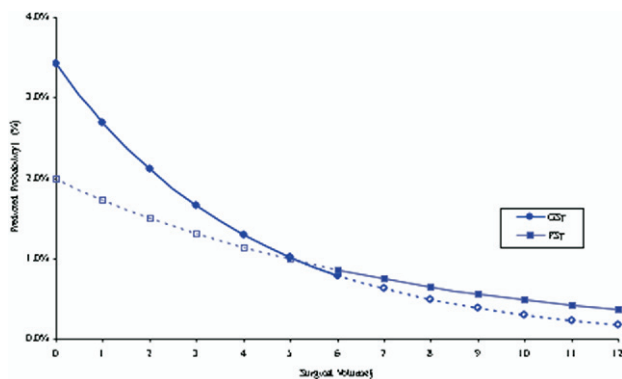
Because pyloromyotomy is so common, it is not practical to recommend that all infants with HPS be operated on by a pediatric surgeon, particularly in rural areas that may not have a pediatric surgeon. Transport to hospitals with high-volume surgeons may have only a small overall impact on morbidity and mortality.<sup>45</sup> A process of education, mentoring, and focusing of community practices to the point that general surgeons who choose to care for children with HPS can maintain adequate volumes and therefore achieve the same outcomes as trained pediatric surgeons is probably a more practical approach.<sup>44</sup>

## Postoperative feeding

A variety of postoperative feeding regimens have been used after pyloromyotomy. Many surgeons impose a period of no feeding, with or without nasogastric suctioning, followed by gradual advancement of amounts and strengths of feeds. This traditional cautious approach came about because of concerns about emesis and possible aspiration. However, evidence to document reduced emesis or morbidity with this approach is limited.<sup>47</sup> A prospective randomized study of three different feeding regimens showed postoperative emesis to be self-limited and independent of the dietary regimen.<sup>48</sup> Retrospective studies have reported shorter postoperative hospital stays in patients receiving accelerated feedings, with either insignificant increase<sup>49</sup> or no increase<sup>50</sup> in vomiting. Similarly, postoperative ad libitum feeding has been shown to result in earlier discharge and no increase in morbidity compared with historical controls.<sup>47</sup> Early ad libitum feeding after laparoscopic pyloromyotomy resulted in significant increase in vomiting in a retrospective review, without any difference in length of stay or complications compared with a more cautious feeding protocol.<sup>51</sup> A long preoperative history of emesis (frequently with electrolyte abnormalities) is thought to be a risk factor for significant postoperative emesis and prolonged stay.<sup>50</sup> Because infants now tend to present earlier in the course of their illness than in the past, and are less compromised,<sup>19</sup> most should be able to tolerate early and accelerated feedings.

## Outcomes: Complications

Pyloromyotomy is associated with a low incidence of morbidity and mortality. A retrospective review of a large number of patients from 2 pediatric surgical centers between 1969 and 1994 revealed a 10% overall complication rate.<sup>52</sup> Over the 25-year period, 901 infants underwent pyloromyotomy via a right upper quadrant incision. Intraoperative complications occurred in 4% of patients (39 duodenal perforations, 1 difficult intubation). Postoperative compli-



PS, Pediatric surgeons; GS, General surgeons

1) Probabilities were calculated based on a logistic regression model.

2) Since few GS did more than 6 pyloromyotomies per year, probabilities of duodenal perforation and surgical volume beyond 6 were only approximated. Similarly since few PS did less than 6 pyloromyotomies per year, probabilities below 6 were also approximated.

**Figure 4** Graph showing perforation rate in pyloromyotomies done by pediatric surgeons and general surgeons. In general, pediatric surgeons had a lower rate of mucosal perforation. However, general surgeons who did a high volume of pyloromyotomies had a perforation rate that approached that of the pediatric surgeons.<sup>44</sup> (Color version of figure is available online.)

cations occurred in 6% (1% wound infection, 3.5% postoperative vomiting beyond 48 hours, and 1 death from delayed diagnosis of Hirschsprung's disease and enterocolitis). There were no incomplete pyloromyotomies. Other large series have varied widely in reported complication rates; 0.3% to 12% for wound infection, 0% to 11.5% for mucosal perforation, and 3% to 60% for postoperative vomiting.<sup>27-29,31,32</sup> In a district general hospital, a perforation rate of 19% was considered acceptable after open pyloromyotomy, as all events were recognized and no morbidity resulted.<sup>53</sup> However, a perforation rate of this degree would not be considered acceptable in most specialized centers. Incomplete pyloromyotomy is reported in 0% to 5.5% of laparoscopic procedures and in 0% to 1.9% of open pyloromyotomies.<sup>23,29,31,32,54</sup> The wide variation between institutions may be due to differences in the definitions of wound infection and postoperative vomiting, the experience of the surgeons and institutions, or the use of administrative data which may result in under-reporting of complications.

Successful management of duodenal perforation is contingent on accurate intraoperative recognition of the complication. The simplest surgical option is to repair the perforation with several mucosal sutures, with or without the addition of an omental patch. Alternatively, some surgeons completely close the myotomy, rotate the pylorus 180°, and perform a second myotomy on the posterior side of the pylorus. Because this is a relatively rare complication, there are no data in the literature that compare these approaches.

Repeat operations after pyloromyotomy are rarely performed, and usually due to an incomplete first operation or less commonly an unrecognized perforation. Most authors recommend doing a second pyloromyotomy on the other side of the pylorus in this situation. Recurrent HPS after few weeks of tolerating feeds and weight gain has also been described, and probably represents a different process than incomplete pyloromyotomy.<sup>55,56</sup> Far more common causes for persistent vomiting postoperatively are gastroesophageal reflux and gastritis; these should be considered if emesis persists, particularly if the vomiting is not after every feed. Contrast radiography can demonstrate reflux or gastric outlet obstruction, but is of little help postoperatively to determine whether there has been an incomplete pyloromyotomy, since the radiological picture does not change perceptibly after surgery.<sup>57</sup> In rare cases, a child with HPS may also have a congenital cause of obstruction such as duodenal web,<sup>17</sup> which may cause persistent obstruction requiring additional surgery. Ultrasound is also of limited value in the postoperative period, as the muscle thickness and length has been shown to take up to 4 to 5 months to return to normal.<sup>58</sup>

Mortality after pyloromyotomy is less than 0.4% in most major centers.<sup>1</sup> Long-term sequelae are rare, but acquired HPS can result from an unrecognized perforation and leak, and small bowel obstruction from adhesions has been described.<sup>52</sup>

## Nonoperative treatment

Before the widespread use of pyloromyotomy, HPS was often treated medically. However, the excellent outcome associated with the Ramstedt's procedure has led to virtual abandonment of nonoperative management of HPS. Recently, medical treatment has been reappraised, primarily outside North America.<sup>59,60</sup> This approach involves intravenous and oral atropine (an acetylcholine inhibitor) in addition to fluid and electrolyte replacement. The theory is that muscular spasm leads to hypertrophy, and then ongoing spasm exacerbates the fixed obstruction that is responsible for the symptoms of HPS. According to the theory, atropine temporarily suppresses muscular contractions and decreases gastrointestinal peristalsis, and therefore breaks the cycle which caused the symptoms. Using intravenous atropine (0.01 mg/kg/day), Kawahara and coworkers treated 19 consecutive patients 6 times a day, 5 minutes before feeding, which were gradually advanced.<sup>61</sup> Patients were converted to oral atropine when they were tolerating full feeds. Ultrasonography was performed at diagnosis and at 3 weeks, 6 months, and 1 year. Atropine treatment was successful in 17 of the 19 patients with the remaining 2 requiring surgery after 9 and 18 days. Total median hospital stay was 13 (range 6-20) days. The median duration of intravenous and subsequent oral atropine was 7 and 44 days, respectively. Pyloric muscle thickness decreased significantly (from 5 mm to 3 mm) 3 weeks after completion of oral atropine and at the same time flow through the pyloric canal was noted. At 6 months, pyloric canal length had shortened. No major complications were reported after the atropine treatment. The authors' recent nonrandomized follow-up study confirmed their preliminary results.<sup>61</sup> Compared with pyloromyotomy ( $n = 40$ ) performed at the same time, the hospital stay was shorter for the surgical patients (mean 5 versus 13 days). Complications in the surgical group were wound infection (10%) and hemorrhagic shock in a patient with hemophilia, compared with a urinary tract infection, upper respiratory tract infection, and a transient elevation of liver function tests in 1 patient each from the atropine group ( $n = 52$ ).

Yamatata and coworkers retrospectively compared consecutive cases of HPS treated either surgically (umbilical incision,  $n = 20$ ) or medically (oral atropine 0.05 mg/kg/d,  $n = 14$ ).<sup>60</sup> Oral feedings were started 3 hours after surgery and gradually increased at 3-hour intervals, and in the atropine group, feedings were gradually advanced after confirming tolerance for oral dextrose solution. With vomiting, the atropine was increased to a predetermined maximum dose of 0.1 mg/kg/day. If oral atropine was not tolerated, a conversion was made to intravenous atropine on day 3 (2 patients). If atropine treatment failed, the infant was referred for a pyloromyotomy no later than 7 days after commencement of treatment. Patients were maintained on intravenous fluid as well throughout the treatment. The authors reported 85% success with the atropine group compared with 100% for the pyloromyotomy group. Atropine was continued until

normalization of the pyloric muscle on ultrasound ( $<3.5$  mm), which took  $3.2 \pm 2.3$  months. This time length was consistent with how long it took the pylorus muscle in the surgical group to return to the same value ( $3.8 \pm 2.0$  months). However, this is quite different than in the aforementioned studies, and this discrepancy, which is noted by the authors, is not explained. The total cost of hospitalization or follow-up visits was significantly less in the medically treated group (including those that had an operation) compared with the surgical group. Two wound infections occurred in the surgical group but no adverse effects in the medical group, and there was no recurrence of vomiting in either. Prolonged hospitalization, skilled nursing, and careful follow up while patient is on the atropine is required. Thus, it is unlikely that atropine will replace surgery for HPS, especially in North America. However, it could be an alternative to pyloromyotomy in children with significant contraindications to anesthesia or surgery.

Endoscopic or image-guided balloon dilation of the pylorus has also been described for patients with HPS. However, preliminary reports documented an unacceptably high rate of both perforation and failure to relieve the obstruction,<sup>62</sup> and this technique has not been widely adopted. Like the use of atropine, it may still have a role for children with a significant contraindication to surgical pyloromyotomy.<sup>63</sup>

## References

- O'Neill JA, Grosfeld JL, Fonkalsrud EW, et al (eds). Principles of Pediatric Surgery (ed 2, chapter 45). St. Louis, MO: Mosby, 2004; 467-70.
- To T, Wajja A, Wales PW, et al. Population demographic indicators associated with incidence of pyloric stenosis. *Arch Pediatr Adolesc Med* 2005;159:520-5.
- Schechter R, Torfs CP, Bateson TF. The epidemiology of infantile hypertrophic pyloric stenosis. *Paediatr Perinat Epidemiol* 1997;11: 407-27.
- Habbick BF, Khanna C, To T. Infantile hypertrophic pyloric stenosis: a study of feeding practices and other possible causes. *CMAJ* 1989; 140:401-4.
- Hernanz-Schulman M. Infantile hypertrophic pyloric stenosis. *Radiology* 2003;227:319-31.
- Ng WT, Lee SY. Hypertrophic pyloric stenosis, congenital or not congenital: a critical overview. *Pediatr Surg Int* 2002;18:563-4.
- Okazaki T, Yamataka A, Fujiwara T, et al. Abnormal distribution of nerve terminals in infantile hypertrophic pyloric stenosis. *J Pediatr Surg* 1994;29:655-8.
- Kobayashi H, O'Brian DS, Puri P. Selective reduction in intramuscular nerve supporting cells in infantile hypertrophic pyloric stenosis. *J Pediatr Surg* 1994;29:651-4.
- Malmfors G, Sundler F. Peptidergic innervation in infantile hypertrophic pyloric stenosis. *J Pediatr Surg* 1986;21:303-6.
- Kusafuka T, Puri P. Altered messenger RNA expression of the neuronal nitric oxide synthase gene in infantile hypertrophic pyloric stenosis. *Pediatr Surg Int* 1997;12:576-9.
- Langer JC, Berezin I, Daniel EE. Hypertrophic pyloric stenosis: ultrastructural abnormalities of enteric nerves and the interstitial cells of Cajal. *J Pediatr Surg* 1995;30:1535-43.
- Ohshiro K, Puri P. Increased insulin-like growth factor-I mRNA expression in pyloric muscle in infantile hypertrophic pyloric stenosis. *Ped Surg Int* 1998;13:253-5.
- Ohshiro K, Puri P. Increased insulin-like growth factor and platelet derived growth factor system in the pyloric muscle in infantile hypertrophic pyloric stenosis. *J Pediatr Surg* 1998;33:378-81.
- Oue T, Puri P. Smooth muscle cell hypertrophy versus hyperplasia in infantile hypertrophic pyloric stenosis. *Pediatr Res* 1999;45:853-7.
- Saur D, Vanderwinden JM, Seidler B, et al. Single-nucleotide promoter polymorphism alters transcription of neuronal nitric oxide synthase exon 1c in infantile hypertrophic pyloric stenosis. *Proc Natl Acad Sci U S A* 2004;101:1662-7.
- White MC, Langer JC, Don S, et al. Sensitivity and cost minimization analysis of radiology versus palpation for the diagnosis of hypertrophic pyloric stenosis. *J Pediatr Surg* 1998;33:913-7.
- Irish MS, Pearl RH, Caty MG, et al. The approach to common abdominal diagnoses in infants and children. *Pediatr Clin North Am* 1998;45:729-72.
- Macdessi J, Oates RK. Clinical diagnosis of pyloric stenosis: a declining art. *Br Med J* 1993;306:553-5.
- Hulka F, Campbell TJ, Campbell JR, et al. Evolution in the recognition of infantile hypertrophic pyloric stenosis. *Pediatrics* 1997;100:e9.
- Hernanz-Schulman M, Sells LL, Ambrosino MM, et al. Hypertrophic pyloric stenosis in the infant without a palpable olive: accuracy of sonographic diagnosis. *Radiology* 1994;193:771-6.
- Cohen HL, Zinn HL, Haller JO, et al. Ultrasonography of pylorospasm: findings may simulate hypertrophic pyloric stenosis. *J Ultrasound Med* 1998;17:705-11.
- Rice HE, Caty MG, Glick PL. Fluid therapy for the pediatric surgical patient. *Pediatr Clin North Am* 1998;45:719-27.
- van der Bilt JDW, Kramer WL, van der Zee DC, et al. Laparoscopic pyloromyotomy for hypertrophic pyloric stenosis. *Surg Endosc* 2004; 18:907-9.
- Tan KC, Bianchi A. Circumbilical incision for pyloromyotomy. *Br J Surg* 1986;73:399.
- Khan AR, Al-Bassam AR. Circumbilical pyloromyotomy: larger pyloric tumours need an extended incision. *Pediatr Surg Int* 2000;16: 338-41.
- Fitzgerald PG, Lau GY, Langer JC, et al. Umbilical fold incision for pyloromyotomy. *J Pediatr Surg* 1990;25:1117-8.
- Leinwand MJ, Shaul DB, Anderson KD. The umbilical fold approach to pyloromyotomy: is it a safe alternative to the right upper-quadrant approach? *J Am Coll Surg* 1999;189:362-7.
- Kim SS, Lau ST, Lee SL, et al. Pyloromyotomy: a comparison of laparoscopic, circumumbilical, and right upper quadrant operative techniques. *J Am Coll Surg* 2005;201:66-70.
- Blumer RME, Hessel NS, van Baren R, et al. Comparison between umbilical and transverse right upper abdominal incision for pyloromyotomy. *J Pediatr Surg* 2004;39:1091-3.
- Alain JL, Grousseau D, Terrier G. Extramucosal pyloromyotomy by laparoscopy. *J Pediatr Surg* 1991;25:1191-2.
- Yagmurlu A, Barnhart DC, Vernon A, et al. Comparison of the incidence of complications in open and laparoscopic pyloromyotomy: a concurrent single institution series. *J Pediatr Surg* 2004;39:292-6.
- Hall NJ, van der Zee J, Tan HL, et al. Meta-analysis of laparoscopic versus open pyloromyotomy. *Ann Surg* 2004;240:774-8.
- Greason KL, Allshouse MJ, Thompson WMR, et al. A prospective, randomized evaluation of laparoscopic versus open pyloromyotomy in the treatment of infantile hypertrophic pyloric stenosis. *Pediatr Endosc Surg Innov Tech* 1997;1:175-9.
- St. Peter SD, Holcomb GW, Calkins CM, et al. Open versus laparoscopic pyloromyotomy for pyloric stenosis. A prospective, randomized trial. *Ann Surg* 2006;244:363-70.
- Pranikoff T, Campbell BT, Travis J, et al. Differences in outcome with subspecialty care: pyloromyotomy in North Carolina. *J Pediatr Surg* 2002;37:352-6.
- Borenstein SH, To T, Wajja A, et al. Effect of subspecialty training and volume on outcome after pediatric inguinal hernia repair. *J Pediatr Surg* 2005;40:75-80.

37. Somme S, To T, Langer JC. Factors determining the need for operative reduction in children with intussusception: a population-based study. *J Pediatr Surg* 2006;41:1014-9.
38. Wennberg DE, Lucas FL, Birkmeyer JD, et al. Variation in carotid endarterectomy mortality in the Medicare population: trial hospitals, volume, and patient characteristics. *JAMA* 1998;279:1278-81.
39. Porter GA, Soskolne CL, Yakimets WW, et al. Surgeon-related factors and outcome in rectal cancer. *Ann Surg* 1998;227:157-67.
40. Saunders M, Williams C. Infantile hypertrophic pyloric stenosis: experience in a district general hospital. *J R Coll Surg Edinb* 1990;35:36-8.
41. Dube S, Dube P, Hardy J, et al. Pyloromyotomy of Ramstedt: experience of a nonspecialized centre. *Can J Surg* 1990;33:95-6.
42. Jahangiri M, Osborne M, Jayatunga A, et al. Infantile hypertrophic pyloric stenosis: where should it be treated? *Ann R Coll Surg Engl* 1993;75:34-6.
43. Maxwell-Armstrong CA, Cheng M, Reynolds J, et al. Surgical management of infantile hypertrophic pyloric stenosis: can it be performed by general surgeons? *Ann R Coll Surg Engl* 2000;82:341-3.
44. Langer JC, To T. Does pediatric surgical specialty training affect outcome after Ramstedt pyloromyotomy? A population-based study. *Pediatrics* 2004;113:1342-7.
45. Ly DP, Liao JG, Burd RS. Effect of surgeon and hospital characteristics on outcome after pyloromyotomy. *Arch Surg* 2005;140:1191-7.
46. Safford SD, Petrobon R, Safford KM, et al. A study of 11,003 patients with hypertrophic pyloric stenosis and the association between surgeon and hospital volume and outcomes. *J Pediatr Surg* 2005;40:967-73.
47. Puapong D, Kahng D, Ko A, et al. Ad libitum feeding: safely improving the cost-effectiveness of pyloromyotomy. *J Pediatr Surg* 2002;37:1667-8.
48. Wheeler RA, Najmaldin AS, Stoodley N, et al. Feeding regimens after pyloromyotomy. *Br J Surg* 1990;77:1018-9.
49. Georgeson KE, Corbin TJ, Griffen JW, et al. An analysis of feeding regimens after pyloromyotomy for hypertrophic pyloric stenosis. *J Pediatr Surg* 1993;28:1478-80.
50. Gollin G, Dosloughlu H, Flummerfeldt P, et al. Rapid advancement of feedings after pyloromyotomy for pyloric stenosis. *Clin Pediatr* 2000;39:187-90.
51. van der Bilt JDW, Kramer WLM, van der Zee DC, et al. Early feeding after laparoscopic pyloromyotomy. The pros and cons. *Surg Endosc* 2004;18:746-8.
52. Hulka F, Harrison MW, Campbell TJ, et al. Complications of pyloromyotomy for infantile hypertrophic pyloric stenosis. *Am J Surg* 1997;173:450-2.
53. White JS, Clements WDB, Heggarty P, et al. Treatment of infantile hypertrophic pyloric stenosis in a district general hospital: a review of 160 cases. *J Pediatr Surg* 2003;38:1333-6.
54. Fujimoto T, Lane GJ, Segawa O, et al. Laparoscopic extramucosal pyloromyotomy versus open pyloromyotomy for infantile hypertrophic pyloric stenosis: which is better? *J Pediatr Surg* 2000;34:370-2.
55. Ankermann T, Engler S, Partsch CJ. Repyloromyotomy for recurrent infantile hypertrophic pyloric stenosis after successful first pyloromyotomy. *J Pediatr Surg* 2002;37:E40.
56. Avolio L, Parigi GB. Redo operation for infantile hypertrophic pyloric stenosis (IHPS) is rare and is often caused by incomplete myotomy or accidental duodenal perforation. *J Pediatr Surg* 2003;38:1129.
57. Jamroz GA, Blocker SH, McAlister WH. Radiographic findings after incomplete pyloromyotomy. *Gastrointest Radiol* 1986;11:139-41.
58. Yoshizawa J, Eto T, Higashimoto Y, et al. Ultrasonographic features of normalization of the pylorus after pyloromyotomy for hypertrophic pyloric stenosis. *J Pediatr Surg* 2001;36:582-6.
59. Kawahara H, Imura K, Nishikawa M, et al. Intravenous atropine treatment in infantile hypertrophic pyloric stenosis. *Arch Dis Child* 2002;87:71-4.
60. Yamataka A, Tsukada K, Yokoyama-Laws Y, et al. Pyloromyotomy versus atropine sulfate for infantile hypertrophic pyloric stenosis. *J Pediatr Surg* 2000;35:338-42.
61. Kawahara H, Takama Y, Yoshida H, et al. Medical treatment of hypertrophic pyloric stenosis: should we always slice the "olive"? *J Pediatr Surg* 2005;40:1848-51.
62. Hayashi A, Giacomantonio JM, Lau HYC, et al. Balloon catheter dilatation for hypertrophic pyloric stenosis. *J Pediatr Surg* 1990;25:1119-21.
63. Ogawa Y, Higashimoto Y, Nishijima E, et al. Successful endoscopic balloon dilatation for hypertrophic pyloric stenosis. *J Pediatr Surg* 1996;31:1712-4.