



## Clinical Update: Vascular Abnormalities of Skin and Soft Tissues

<sup>1</sup>Prof. Andrew Burd  
MD, FRCS, FHKAM(Surgery)

<sup>2</sup>Dr. Ada GY Zeng  
MBChB, MRCS

<sup>1</sup>Dr. Stephanie CK Lam  
MBChB, MRCS



Prof. Andrew Burd

<sup>1</sup>Division of Plastic & Reconstructive and Aesthetic Surgery, Department of Surgery, The Chinese University of Hong Kong, Prince of Wales Hospital

<sup>2</sup>Department of Surgery, Tuen Mun Hospital

*This article has been selected by the Editorial Board of the Hong Kong Medical Diary for participants in the CME programme of the Medical Council of Hong Kong (MCHK) to complete the following self-assessment questions in order to be awarded one CME credit under the programme upon returning the completed answer sheet to the Federation Secretariat on or before 30 November 2007.*

### Introduction

Although it has been over twenty years since Mulliken and Glowacki wrote their classic paper regarding the clinical distinction of haemangiomas and vascular malformations<sup>1-2</sup> it is still not uncommon to meet patients in their late teens who are still waiting for 'haemangiomas' to spontaneously resolve. Table 1 summarises the main distinctions between the two types of vascular abnormalities. It should be noted that although vascular malformations will be present at birth they may not always be clinically apparent at birth and indeed may not be noticed until several years after birth. The most important differentiating feature is the rapid growth of haemangiomas in the first year of life and the subsequent involution. This distinction is shown in Figure 1.

### Haemangioma

Haemangiomas are the most common tumour of infancy and typically appear as a small reddish macule<sup>3</sup>. 80% occur within the first month of life. The macule quickly grows and becomes raised and lobulated. The appearance is not unlike a strawberry hence the name strawberry naevus. At a cellular level the vascular endothelium in the proliferating haemangioma is cycling at a very high rate<sup>4</sup>. The mitotic index is extremely high and the cycling time can be as short as twenty four hours. VEGF is expressed very highly in these cells and can be detected in the circulating blood. bFGF expression is also significantly upregulated. The pattern of subsequent cytokine expression and mitotic index is shown in Figure 2.

Whilst the vast majority of haemangiomas involve the skin, they can occur subcutaneously, appearing as a bluish patch under the skin. This can cause a rapidly developing swelling which then involutes as in the cutaneous lesion. Most haemangiomas can be treated conservatively with an expectant strategy. The parents need to be reassured that the lesion(s) will involute and in most cases surgery is relegated to some minor procedures to remove the redundant skin.

There are occasions, however, when haemangiomas do

need more active intervention. Table II shows intrinsic and extrinsic causes for concern. Of note, the 'Kasabach-Merritt' syndrome has been described as a rare presentation of thrombocytopenia associated with haemangiomas. This association has been erroneously made and the syndrome is but a feature of the rare kaposiform haemangioendothelioma. The management of rapidly growing haemangiomas which are causing visual field obstruction is an indication for urgent intervention. There are a number of both non-invasive and invasive options depicted in Tables III. The first line of treatment with a rapidly developing lesion causing visual field obstruction is oral steroid therapy. The response to oral steroids is variable and will depend in part on the stage at which they are used. The response in 30-40% of cases can be quite rapid; in another 30-40% of cases the response still occurs but is slower in developing. In a smaller number there is no response<sup>5</sup>.

Interferon alpha 2a has been used as a subcutaneous injection in life threatening haemangiomas. Although there are reports of clinical control and regression of the lesions, there are also reports of spastic diplegia arising as a complication of this treatment<sup>6</sup>.

Compression therapy has been tried for haemangiomas but there is no evidence to indicate that this speeds up natural involution of the lesion.

With regard to the invasive, medical treatment, intralesional steroids have been tried but they are no more effective than systemic steroids. OK-432 is a denatured streptococcal protein which acts supposedly by stimulating the immune response and speeding up the resolution of the haemangioma<sup>7</sup>. Sclerosing agents have been tried but the indications for such intervention have to be clearly understood. The correct diagnosis has to be made and the decision to intervene has to be balanced against non-intervention and spontaneous involution. The outcome has to be considered and treatment with sclerosants should be limited to haemangiomas where the site is not of a major aesthetic concern. Surgical debulking has to be considered in the same context with regard to the long term effects. Surgery involving extensive scarring should be avoided if the alternative is awaiting natural resolution and lesser scarring<sup>8</sup>.



Laser treatment for haemangiomas is generally unsatisfactory. The biological mechanism of action is referred to as selective photothermolysis. The oxyhaemoglobin complex is selectively targeted by laser energy close to the third absorption spectral peak (577nm). Laser energy is converted to heat which dissipates to destroy the surrounding vessel wall. The limited penetration of the laser energy means that only superficial lesions are accessible to treatment. Because of the physical dispersion of the thermal energy, laser works best in slow flow lesions with small vessels. Nevertheless lasers can be effective in small lesions and the application in early haemangiomas has yet to be evaluated<sup>9</sup>.

## Vascular Malformations (V.M.)

The term V.M. refers to lesions where the anatomy and morphology of the vessels are abnormal although the vascular endothelium is normal. These lesions can either be high, low or mixed flow lesions (Table IV).

### Capillary Malformations

These are typically referred to as Port Wine Stains and can be classified according to the Waner Grading system<sup>10</sup>.

- Grade I lesions: vessel diameters are in the 80  $\mu\text{gm}$  range. These lesions are light pink macules.
- Grade II lesions: vessel diameters measure up to 120  $\mu\text{gm}$ . these lesions are darker pink macules.
- Grade III lesions: vessel diameters measure up to 150  $\mu\text{gm}$ . These lesions are red macules.
- Grade IV lesions: vessel diameters are greater than 150 $\mu\text{gm}$ . These lesions are purple and may become papular.

The present treatment of choice is laser therapy. Previously other treatments have been tried, in particular radiation. This unfortunately resulted in longer term post-radiation skin stigmata (Figure 3). Although laser has improved the outcome of patients with port-wine stains the results are unpredictable and the patients must be counselled at the outset that complete clearing of the lesions is most unlikely and that the response to treatment will plateau (Figure 4). The management of the resistant port wine stain is very difficult and the options are limited; using cosmetic camouflage or excising and reconstructing with grafts or flaps.

## Venous Lesions

The key to the management of venous lesions is accurate diagnosis. History and clinical examination will differentiate haemangiomas from vascular malformations. Ultrasound examination by a well trained operator can give information about the flow characteristics and the architecture of the lesion. The amount of parenchyma and the nature of the vascular spaces, (for example 'lakes' or 'honey-comb') can influence the treatment. MRI is used for assessing the anatomical extent of the lesion. In the low flow venous lesion it is acceptable to surgically debulk it removing

only that part which is giving rise to the most concern. Figure 5a-d shows a vascular malformation that involved the lower lip. There were some problems with oral continence and speech. Two years after limited bulking shows the patient with good oral continence, clear speech but still with residual (not recurrent) malformation involving the right cheek.

The management of diffuse venous malformations can be very challenging as the symptoms are usually mild and the major concern is the appearance. The general strategies used are to treat these lesions with sclerosants or sutures which will produce intralesional scarring and reduction in size of the lesion. There have been reports of producing targeted scleroses using intralesional copper wires<sup>11,12</sup>.

## Lymphatic Lesions

These may be microcystic, macrocystic or a combination of the two. The lymphangioma is an example of a microcystic lesion and the architecture is characterised by a 'honey comb' of connective tissue septa compartmentalising the cystic lesion. The cystic hygroma is an example of a macrocystic lymphatic malformation.

Most lymphatic malformations are present at birth or appear within the first two years of life. They rarely involute spontaneously. They may enlarge if they become infected or bleeding occurs inside the lesion.

Lymphatic malformations can be treated by intralesional injection of OK-432. If surgery is performed it is important to fully excise the lesion to prevent recurrence.

## High Flow Lesions

These are either arterial or arterio-venous malformations. The solitary arterial malformations are uncommon and may present as pulsatile subcutaneous lesions which turn out to be aneurysms or collections of tortuous vessels.

The arterio-venous malformations are more common and whilst the anatomical abnormality will be present at birth the lesions may only become clinically apparent later in infancy or childhood. The lesions are conveniently classified according to the modified Schobinger classification<sup>13</sup> (Table V).

When lesions reach stage 4 they are life threatening. Figure 6a-b shows the left leg of a patient admitted with high output cardiac failure associated with an AVM. The MRI scan shows that the increase in leg size is predominantly associated with the enlargement of the subcutaneous tissues. When history, examination, ultrasound and MRI indicate that there is a high flow AVM, a diagnostic angiogram should be performed to identify the feeding vessels. Interventional radiology is an essential part of the treatment of such lesions. After correcting clotting abnormalities, pre-operative embolisation should be performed. Vascular embolisation can be achieved using a variety of substances including silicone spheres, stainless steel



coils, foam and glue. The role of embolisation is to facilitate surgery and the surgical resection should be as complete as possible to prevent recurrence of the AVM. With extensive resection, complex reconstructions will be needed (Figure 7a-d). These reconstructions will often need to be staged to optimise both the aesthetic and functional aspects<sup>14</sup>. There are occasions where the lesions are so extensive that complete resection is not possible. Figure 8a-c shows an extensive AVM of the left chest wall that involved skin, subcutaneous tissues, muscles, pleura and pericardial tissues. Surgery had been deferred due to the extent of the lesion but with the onset of puberty the lesion grew rapidly and there was daily bleeding from the cutaneous nodules. After extensive counselling and discussions regarding the risks of surgery the patient underwent pre-operative embolisation of perforators from the internal mammary artery. Embolisation was not carried out of the lumbar artery perforators due to the extensive vascular plexi in the longitudinal spinal muscles and the risk of spinal cord ischaemia. Excisional surgery was performed leaving the intercostal muscles (Figure 9) and the defect reconstructed with Integra (Figure 10). The patient remains well eighteen months after surgery although the possibility of recurrence remains (Figure 11a-c).

Surgical treatment in vascular abnormalities can range from a minor skin excision to an ultramajor excision with very real risks of intra-operative mortality. There are no shortcuts in such surgery and a multi-specialty approach is essential. Special points of note in the preoperative consent are listed in Table VI.

## Syndromes Associated with Vascular Lesions

### *Sturge-Weber Syndrome*

The Sturge-Weber Syndrome (SWS) is a neurocutaneous disorder with angiomas involving the leptomeninges and skin of the face, typically in the V1 and V2 distributions of the trigeminal nerve. It is also called encephalotrigeminal angiomatosis. SWS is caused by residual embryonal blood vessels and their secondary effects on surrounding brain tissue. SWS is referred to as complete when both CNS and facial angiomas are present and incomplete when only one area is affected. Because of possible associated anomalies these patients should be referred for specialist investigation and management.

### *Klippel-Trenaunay-Weber Syndrome*

Klippel-Trenaunay-Weber Syndrome is characterised by a triad of port wine stain, varicose veins, and bony and soft tissue hypertrophy involving an extremity. The exact cause of Klippel-Trenaunay-Weber Syndrome (KTWS) is unknown. Most cases are sporadic, although a few cases in the literature report an autosomal dominant pattern of inheritance<sup>15</sup>.

KTWS generally affects a single extremity, although cases of multiple affected limbs have been reported. The leg is the most common site followed by the arms, the trunk, and rarely the head and the neck. Most patients demonstrate all 3 signs of the clinical syndrome: port wine stain, varicose veins, and bony and soft tissue hypertrophies.

Other features include lymphatic obstruction, spina bifida, hypospadias, polydactyly, syndactyly, oligodactyly, hyperhidrosis, hypertrichosis, paresthesia, decalcification of involved bones, chronic venous insufficiency, stasis dermatitis, poor wound healing, ulceration, thrombosis, and emboli<sup>16</sup>. As with Sturge-Weber syndrome these patients need specialised investigation and management.

### *Osler-Weber-Rendu Syndrome*

Osler-Weber-Rendu Syndrome, also known as hereditary haemorrhagic telangiectasia, is an autosomal dominant disorder identified typically by the triad of telangiectasia, recurrent epistaxis, and a positive family history for the disorder. The disease is caused by an inherited defect. Currently 2 loci have been identified associated with Osler-Weber-Rendu Syndrome, one on chromosome arm 9q33-q34 and a second on chromosome arm 12q. The major cause of morbidity and mortality due to this disorder lies in the presence of multiorgan arterio-venous malformations (AVMs) and the associated haemorrhage that may accompany them. The disease has a wide spectrum of presentations; patients may be asymptomatic or have multiple organ involvement, presenting at any age. The clinical manifestations of Osler-Weber-Rendu disease are caused by the development of abnormal vasculature, including telangiectases, AVMs, and aneurysms<sup>17</sup>.

## History

Presentation will be influenced by the site of the pathology.

1. Nasal mucosa: Epistaxis is the most common manifestation of the disease and occurs in up to 90% of affected patients.
2. GI tract: Recurrent painless GI bleeding occurs in 10-40% of patients and generally occurs later in life than epistaxis.
3. Pulmonary vasculature  
Pulmonary AVMs are present in 15-20% of patients with the disease<sup>18</sup>. Haemoptysis results from either telangiectasia of the trachea and bronchi or pulmonary arterio-venous (AV) fistulas.
4. Brain involvement  
Neurologic involvement occurs in 8-12% of patients with Osler-Weber Rendu Syndrome. A history of headache, seizures, and focal neurologic symptoms may be found on questioning<sup>19</sup>. Stroke and brain abscess are more common in these patients. Fatigue may be elicited on history and may be due to an iron deficiency anaemia caused by recurrent blood loss. Liver involvement may cause right upper quadrant (RUQ) pain, jaundice, symptoms of high-output cardiac failure, and bleeding from oesophageal varices. Migraine headaches are present in 50% of patients. Although the reason is unclear, the headaches seem to be associated with pulmonary AVMs.

### *Maffucci's Syndrome*

Maffucci Syndrome (enchondroma with multiple angiomas) is a rare genetic disorder. It is characterized by benign enlargements of cartilage (enchondromas);



bone deformities; and dark, irregularly shaped vascular malformations. The disease manifests early in life, usually around the age of 4 or 5 years, with 25% of cases being congenital. The disease appears to develop from mesodermal dysplasia early in life<sup>20</sup>.

Maffucci Syndrome affects the skin and the skeletal system. Superficial and deep venous malformations often protrude as soft nodules or tumours usually on the distal extremities, but they can appear anywhere. The vascular malformations are usually asymmetric and manifest as blue subcutaneous nodules that can be emptied by pressure. Thrombi often form within the vessels and develop into phleboliths. Venous-lymphatic malformations can occur but are much less common. Enchondromas are benign cartilaginous tumours that can appear anywhere, but they are usually found on the phalanges and the long bones. These bone abnormalities are usually asymmetric and cause secondary fractures. About 30-37% of enchondromas can develop into a chondrosarcoma.

### Complications

Neoplastic changes occur in enchondromas, chondrosarcoma being the most common affecting about 30% of patients<sup>21</sup>. Enchondromas can cause fractures, leading to further complications, such as shortened or unequal length limbs.

## Differential Diagnosis of Vascular Lesions

Figure 12 shows a pre-operative view of a patient who has had a slow growing soft tissue lesion on the left side of the face. Ultrasound and MRI both suggested a vascular malformations with 60% parenchyma, phleboliths, large vascular channels and a low flow lesion. At operation a diffuse and very vascular lesion was removed which involved the parotid gland. Total parotidectomy with sacrifice of the facial nerve was performed. The surgical bed was packed for 48 hours (Figure 13a) before the patient was returned to theatre for nerve reconstruction with sural nerve grafts (Figure 13b). Definitive histology revealed the lesion to be a highly vascular plexiform neurofibroma.

Pyogenic granuloma is a form of haemangioma with rapidly proliferating blood vessels. Figure 14 shows a typical case involving the right upper eyelid of an infant. Later in life it is very important to send suspicious tissues for histological analysis. The raised vascular lesion on the right temple of an elderly patient in Figure 15 turned out to be a squamous cell carcinoma.

Paragangliomas can be very vascular tumours and can be mistaken for vascular malformations. The right infraclavicular lesion shown in Figure 16 was investigated with U/S, MRI and Angiography. Pre-operative embolisation was performed before surgical excision. The final histology turned out to be a paraganglioma.

## Summary

(1) Haemangiomas and Vascular Malformations are very

- (1) Haemangiomas and Vascular Malformations are very different entities.
- (2) Distinguished by History and Examination.
- (3) Use U/S to demonstrate the flow rate and also the tissue architecture.
- (4) Use MRI to demonstrate the extent of the lesion.
- (5) Use angiography in high flow lesions to identify feeding vessels.
- (6) Debulking can be considered in low flow lesions.
- (7) Pre-operative embolisation and complete excision should be undertaken for high flow lesions.
- (8) Treatment must involve a multi-specialty approach to achieve optimum results.

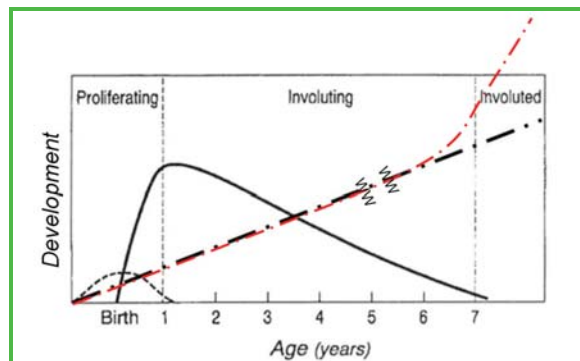


Fig 1 A diagrammatic representation of the time-growth curves of vascular lesions. The solid black line represents the typical haemangiomas; the dotted line represents the course of the rare congenital haemangiomas; the dash-dot line represents the vascular malformations.

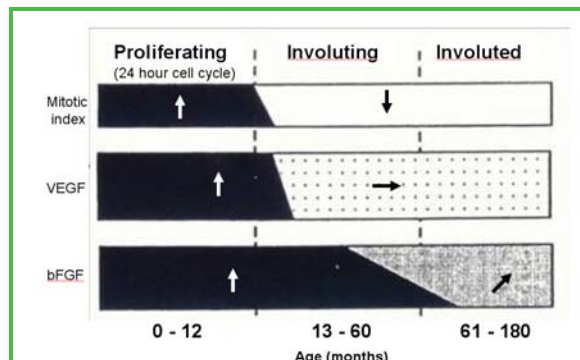


Fig 2 The cellular kinetics and cytokine expression of haemangiomas. (Modified from Cohen MM. Vasculogenesis, angiogenesis, hemangiomas, and vascular malformations. American Journal of Medical Genetics 2002;108:265-274)

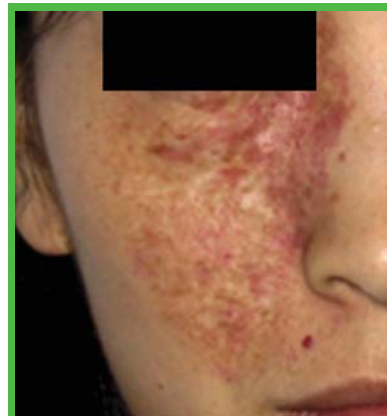

Fig 3 Post radiation skin changes.

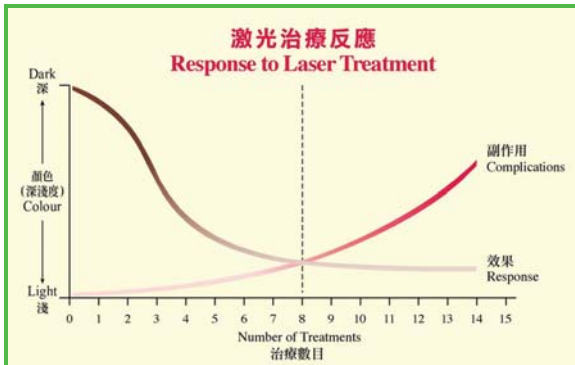


Fig 4 A patient information diagram showing the expectation of an initial good response to laser treatment that typically stabilises. Continued treatment produces little further improvement but the risk of complications increases.

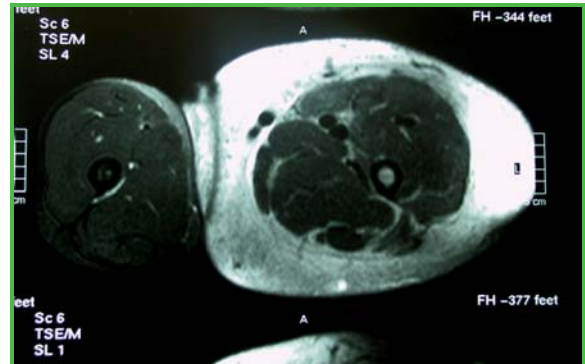


Fig 6b MRI showing grossly similar muscle bulk in both thighs but major increase in subcutaneous tissue vascularity.

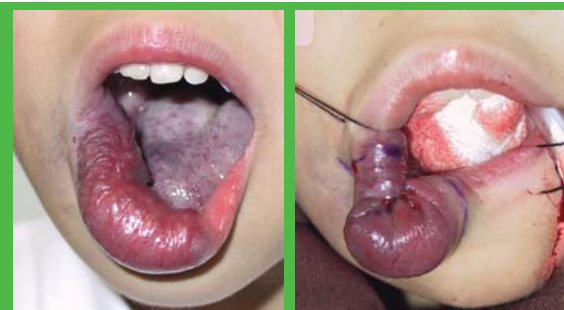

Fig 5a A sloppy and redundant lower lip causing speech and drinking difficulties.

Fig 5b Surgical debulking.

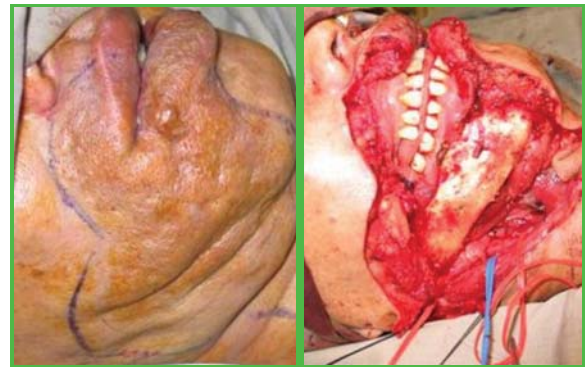

Fig 7a AVM of Right cheek.

7b Radical excision showing extensive full thickness defect.

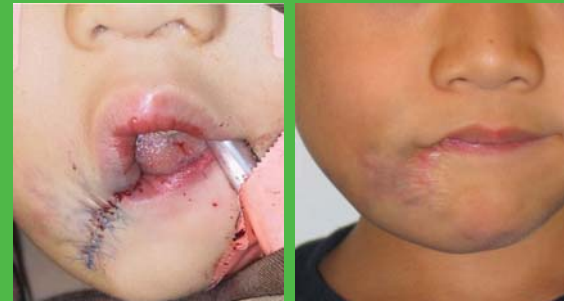

Fig 5c Restoration of oral continence.

Fig 5d Two years post op. Asymptomatic but with residual abnormality in cheek.

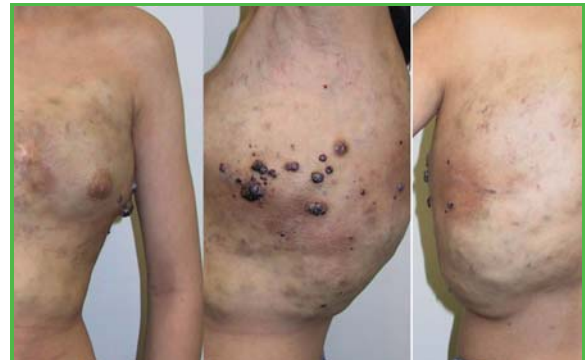

Fig 8a-c Vascular malformation affecting left chest wall.

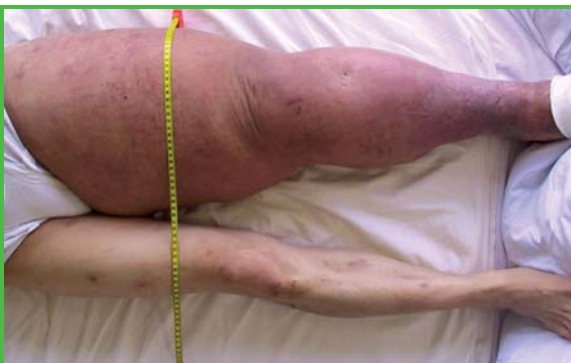

Fig 6a AVM affecting left lower limb and causing heart failure.

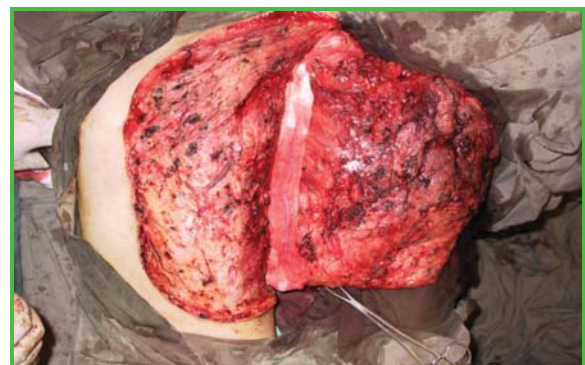

Fig 9 Enbloc resection with meticulous haemostasis.

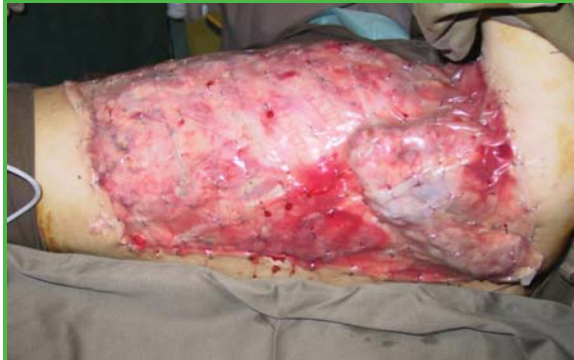

Fig 10 Soft tissue defect covered with IntegraR dermal regeneration template.

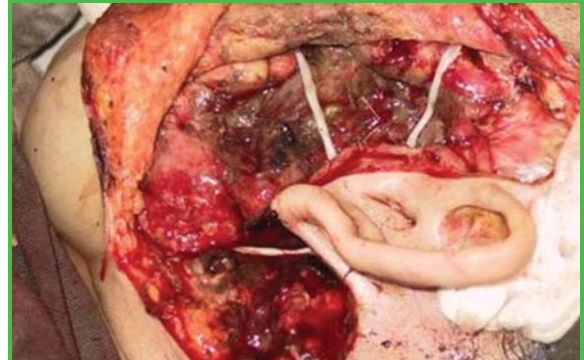


Fig 13b Facial nerve reconstruction 48 hours later with thickened sural nerve grafts.

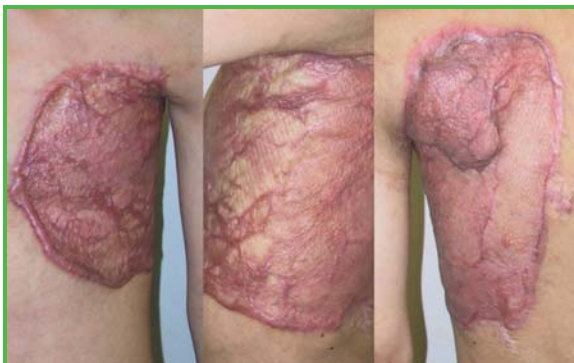


Fig 11a-c Nine months post up.

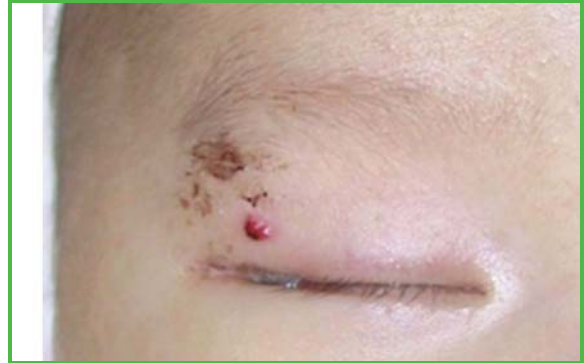

Fig 14 A typical pyogenic granuloma in a three month old child following minor trauma.

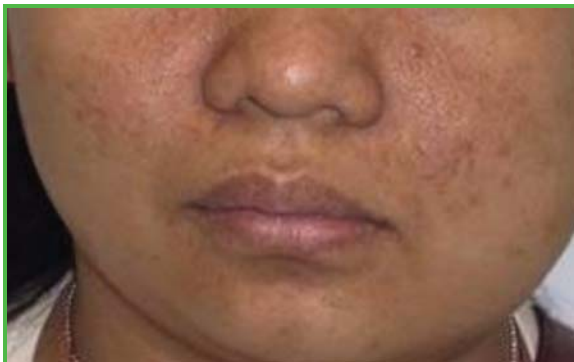

Fig 12 Unilateral soft tissue facial swelling involving left cheek.

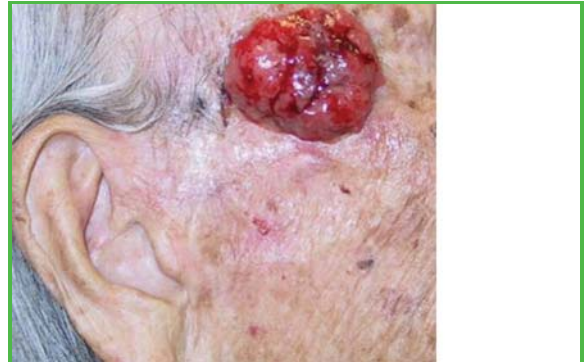

Fig 15 A friable vascular lesion in an elderly lady that proved to be a squamous cell carcinoma.

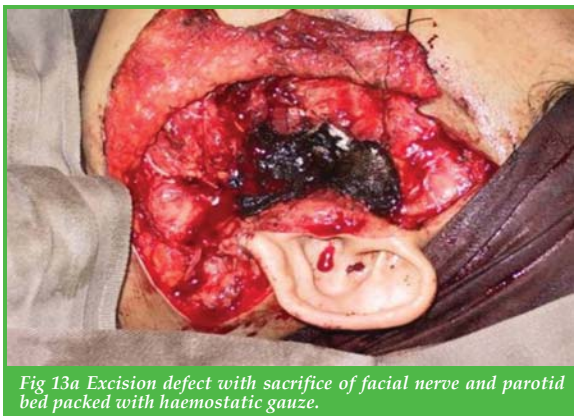

Fig 13a Excision defect with sacrifice of facial nerve and parotid bed packed with haemostatic gauze.

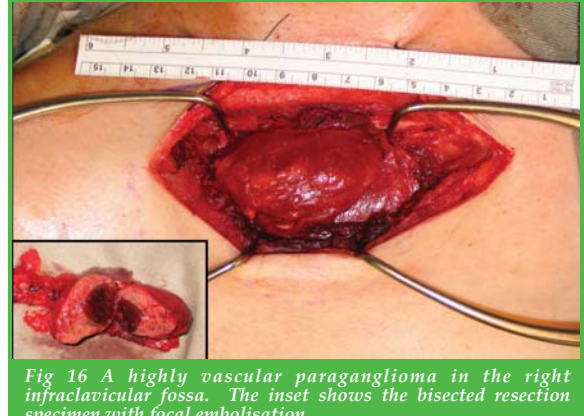


Fig 16 A highly vascular paraganglioma in the right infraclavicular fossa. The inset shows the bisected resection specimen with focal embolisation.



Table I Classification of vascular abnormalities.

Vascular Abnormalities (Mulliken and Glowacki)	
Haemangiomas(tumour)	Vascular Malformations (anatomy)
<ul style="list-style-type: none"> <li>Usually not present at birth</li> <li>Rapidly increase in size</li> <li>Involute</li> <li>F:M = 3:1</li> <li>60% Head and Neck</li> <li>Most common tumour of infancy</li> <li>"Strawberry naevus"</li> </ul>	<ul style="list-style-type: none"> <li>Present at birth (but may not be clinically apparent)</li> <li>Grow in proportion to body size</li> <li>Can degenerate but also can hypertrophy (AVM)</li> </ul>

Table II Serious complications of haemangiomas that need active intervention.

Critical Compromise	
Intrinsic	Extrinsic
<ul style="list-style-type: none"> <li>Bleeding</li> <li>Ulceration</li> <li>Kasabach - Merritt Syndrome</li> <li>Thrombocytopenia associated with kaposiform haemangioendothelioma NOT common haemangioma.</li> </ul>	<ul style="list-style-type: none"> <li>Upper eyelids</li> <li>Deprivation amblyopia and failure to develop binocular vision.</li> <li>Corneal distortion and astigmatism.</li> <li>Airway obstruction</li> </ul>

Table III Treatments for complicated haemangiomas.

Haemangiomas - Treatments
<p><b>Non-Invasive</b></p> <ul style="list-style-type: none"> <li>Systemic steroids 2mg/kg/day                             <ul style="list-style-type: none"> <li>Some response in 50-90% of cases</li> </ul> </li> <li>Interferon alpha 2a subcut</li> <li>Compression therapy</li> </ul>
<p><b>Invasive</b></p> <ul style="list-style-type: none"> <li>Intralesional steroids</li> <li>Intralesional OK-432 (from denatured streptococcal protein)</li> <li>Intralesional sclerosing agents (Hypertonic saline, glucose)</li> <li>Surgical debulking</li> </ul>

Table IV Classification of vascular malformations.

Vascular Malformations	
Low Flow	High Flow
<ul style="list-style-type: none"> <li>Capillary</li> <li>Venous</li> <li>Lymphatic</li> </ul>	<ul style="list-style-type: none"> <li>Arterial</li> <li>Arterio-venous</li> </ul>

Table V Staging of arterio-venous malformations

Schobinger Staging of AVM
<ul style="list-style-type: none"> <li>Stage 1: A blue-skin blush</li> <li>Stage 2: A mass associated with a bruit and a thrill</li> <li>Stage 3: A mass associated with ulceration, bleeding and pain</li> <li>Stage 4: Stage 3 lesions producing heart failure</li> </ul>

Table VI Important addition aspects of the informed consent when contemplating surgical excision of the complex vascular malformation.

Informed Consent
<ul style="list-style-type: none"> <li>Bleeding</li> <li>Death on table</li> <li>Incomplete excision</li> <li>Recurrence</li> <li>Residual deformity</li> <li>Nerve damage (in Head and Neck)</li> </ul>

References

- Mulliken JB, Glowacki J. Hemangiomas and vascular malformations in infants and children: a classification based on endothelial characteristics. *Plast Reconstr Surg* 1982;69:412-422.
- Mulliken JB, Young AE. *Vascular Birthmarks - Hemangiomas and Malformations*. W B Saunders Company: Philadelphia, 1988.
- Gampper TJ, Morgan RF. Vascular anomalies: hemangiomas. *Plast Reconstr Surg* 2002;110:572-585.
- Glowacki J, Mulliken JB. Mast cells in hemangiomas and vascular malformations. *Pediatrics* 1982;70:48-51.
- Hasan Q, Tan ST, Gush J, Peters SG, Davis PF. Steroid therapy of a proliferating hemangioma: histochemical and molecular changes. *Pediatrics* 2000;105:117-120.
- Worle H, Maass E, Kohler B, Treuner J. Interferon alpha-2a therapy in haemangiomas of infancy: spastic diplegia as a severe complication. *European Journal of Pediatrics* 1999;158:344.
- Kim KH, Sung MW, Roh JL, Han MH. Sclerotherapy for congenital lesions in the head and neck. *Otolaryngol Head Neck Surg* 2004;131:307-316.
- McCarthy JG, Borud LJ, Schreiber JS. Hemangiomas of the nasal tip. *Plast Reconstr Surg* 2002;109:31-40.
- Waner M. Recent developments in lasers and the treatment of birthmarks. *Arch Dis Child* 2003;88:372-374.
- Hemangiomas and Vascular Malformations of the Head and Neck. Waner M, Suen JY, eds. New York: Wiley-Liss, 1999.
- Zhou PL. Therapeutic coagulation induced in cavernous hemangioma by use of percutaneous copper needles. *Plast Reconstr Surg* 1992;89:613-622.
- Ogunsalu C, Fray D, Lewis A. Surgery combined with copper wire implantation in the management of cavernous orofacial haemangiomas. *Australian Dental Journal* 2000;45:55-60.
- Kohout MP, Hansen M, Pribaz J, Mulliken JB. Arteriovenous malformations of the head and neck: natural history and management. *Plast Reconstr Surg* 1998;102:643-654.
- Tark KC, Chung S. Histologic change of arteriovenous malformations of the face and scalp after free flap transfer. *Plast Reconstr Surg* 2000;106:87-93.
- Aelvoet GE, Jorens PG, Roelen LM. Genetic aspects of the Klippel-Trenaunay Syndrome. *Br J Dermatol* 1992;126:603-607.
- Samuel M, Spitz L. Klippel-Trenaunay Syndrome: clinical features, complications and management in children. *Br J Surg* 1995;82:757-761.
- Haitjema T, Westermann CJ, Overtom TT. Hereditary hemorrhagic telangiectasia (Osler-Weber-Rendu disease): new insights in pathogenesis, complications, and treatment. *Arch Intern Med* 1996;156:714-719.
- Kjeldsen AD, Oxhøj H, Andersen PE. Pulmonary arteriovenous malformations: screening procedures and pulmonary angiography in patients with hereditary hemorrhagic telangiectasia. *Chest* 1999;116:432-439.
- Kikuchi K, Kowada M, Sasajima H. Vascular malformations of the brain in hereditary hemorrhagic telangiectasia (Rendu-Osler-Weber disease). *Surg Neurol* 1994;41:374-380.
- Spitz JL. Maffucci syndrome. In: *Genodermatosis, A Full-Color Clinical Guide to Genetic Skin Disorders*. Baltimore: Lippincott Williams & Wilkins, 1995;106-107.
- Albregts AE, Rapini RP. Malignancy in Maffucci's Syndrome. *Dermatol Clin* 1995;13:73-78.



### MCHK CME Programme Self-assessment Questions

Please read the article entitled "Clinical Update: Vascular Abnormalities of Skin and Soft Tissues" by Prof. Andrew Burd, Dr. Ada GY Zeng and Dr. Stephanie CK Lam, and complete the following self-assessment questions. Participants in the MCHK CME Programme will be awarded 1 CME credit under the Programme for returning completed answer sheets via fax (2865 0345) or by mail to the Federation Secretariat on or before 30 November 2007. Answers to questions will be provided in the next issue of The Hong Kong Medical Diary.

Questions 1-10: Please answer T (true) or F (false)

1. Both vascular malformations and hemangiomas will be apparent at birth.
2. Because of its eventual involution, hemangioma never needs surgical intervention.
3. Spastic diplegia is a complication of oral steroid therapy.
4. Laser works best in slow flow lesions with small vessels.
5. Laser for port-wine stain can usually completely clear the lesion.
6. For venous lesions, ultrasound is used to assess flow while MRI is used to assess extent.
7. Sturge-Weber syndrome is also called encephalotrigeminal angiomatosis.
8. 60% of enchondroma in Maffucci's syndrome develop into chondrosarcoma.
9. Differential diagnosis of vascular lesions include plexiform neurofibroma, paraganglioma, pyogenic granuloma and squamous cell carcinoma.
10. Schobinger staging of arterio-venous malformations divide them into four categories according to signs and symptoms.

### ANSWER SHEET FOR NOVEMBER 2007

Please return the completed answer sheet to the Federation Secretariat on or before 30 November 2007 for documentation. 1 CME point will be awarded for answering the MCHK CME programme (for non-specialists) self-assessment questions.

## Clinical Update: Vascular Abnormalities of Skin and Soft Tissues

<sup>1</sup>Prof. Andrew Burd

MD, FRCS, FHKAM(Surgery)

<sup>2</sup>Dr. Ada GY Zeng

MBChB, MRCS

<sup>1</sup>Dr. Stephanie CK Lam

MBChB, MRCS

<sup>1</sup>Division of Plastic & Reconstructive and Aesthetic Surgery, Department of Surgery,  
The Chinese University of Hong Kong, Prince of Wales Hospital

<sup>2</sup>Department of Surgery, Tuen Mun Hospital

1  2  3  4  5  6  7  8  9  10

Name (block letters): \_\_\_\_\_ HKMA No.: \_\_\_\_\_

HKID No.: \_\_\_\_ - \_\_\_\_ X X (x)

Other Membership No.  
(please indicate): \_\_\_\_\_

Contact TelNo.: \_\_\_\_\_

### Answers to October 2007 issue

Quality of life and orthodontic treatment need related to Occlusal indices

1. T    2. F    3. F    4. T    5. F    6. T    7. F    8. F    9. T    10. F